

Clinicopathological Investigations of the Role of Estrogen Receptors Alpha and Estrogen Hormone in Gynecomastia

KHALED SADEK, M.D., M.R.C.S.; HATEM EL-SAHAR, M.D., M.R.C.S. and MINA FAYEK, M.Sc.

The Department of Plastic Surgery, Faculty of Medicine, Cairo University

ABSTRACT

Background: Patients with gynecomastia are anxious because the muscular chest symbolizes manhood and strength. Our aim of the study was to test the relationship between gynecomastia and both estrogen hormone blood level and estrogen tissue receptors.

Methods: The study was conducted in the Plastic Surgery Department, Cairo University Hospital, during the period from January 2015 to February 2016. We recruited males between 18 to 60 years presenting with gynecomastia and duration more than one year. Laboratory investigations including hormonal profile, especially estrogen E2 level were made. After surgery, all biopsies were subjected to histopathological examination and immunohistochemical detection of estrogen receptors.

Results: Twenty-two subjects were included in the analysis of this study. The mean age of presentation was 28.3 years with 75% of them are teenagers/young adults. Fifteen patients were grade II, 5 grade III and 2 grade IV. Estrogen hormone was elevated only in two subjects. Histopathological examination of the biopsies revealed that 14 subjects (63.6%) were glandular in nature and only eight subjects (36.4%) were fatty in nature.

Twelve cases were ER- α positive and 10 cases were negative. There was no significant ($p>0.05$) association between the nature of gynecomastia either glandular or fatty, and the side, the grade, the blood level of thyroid hormone and estrogen hormone. However, the age at presentation was significantly ($p=0.03$) lower in cases with fatty gynecomastia (22.38 ± 4.17 years) than in cases with glandular gynecomastia (31.64 ± 13.51 years).

Positive ER- α significantly ($p=0.005$) higher in cases with glandular gynecomastia (11 cases positive) than in cases with fatty gynecomastia (1 case, only). The age at presentation was significantly ($p=0.04$) lower in cases with negative ER- α (22.90 ± 3.84 years) than in cases with positive ER- α (32.75 ± 14.37 years). All cases with negative ER- α were significantly ($p=0.030$) bilateral.

Conclusion: There is an association between ER- α and glandular gynecomastia. Thus, it may play a role in its development. A further large-sample study is recommended to allow a real evidence and quantification of this relationship.

Key words: Gynecomastia – Estrogen receptors – Male breast.

INTRODUCTION

In men, the benign enlargement of breast tissue (gynecomastia) is encountered in infancy, adolescence, and old age. The condition is observed in approximately 30% adults but may be found at higher rates in adolescents [1]. The majority of gynecomastia cases are essentially idiopathic; however, many cases are secondary to a systemic disease. It is understood that it is related to either an increase in estrogens, a decrease in androgens, or a deficit in androgen receptors [2].

Many studies in the medical literature have addressed the expression of Estrogen Receptors (ER) in patients with gynecomastia in term of histopathological analyses [3-6].

The manhood is of extreme importance for males. Thus patients with gynecomastia become anxious seeking medical counsel, making this presentation somewhat common in primary care settings. Thus, the pathoetiology of the condition is important. Many hormones were supposed to affect male breast. Apart from testosterone, receptors for other hormones like estrogen, progesterone, prolactin, Luteinizing Hormone (LH) and Human Chorionic Gonadotropin (hCG) were identified [7]. Changes in their levels account for the development of gynecomastia [8].

In all vertebrates, among the different forms of natural estrogen, estradiol is the most abundant and potent [9]. In males, certain tissues express the enzyme responsible for androgens conversion to estradiol or estrone which is known as aromatase. These sites include the reproductive tract, the bone, and adipose tissues [10].

To best of our knowledge, only one study showed a relationship between Estrogen Receptor (ER) alpha gene and gynecomastia [5]. Another

study reported that estrogen receptors were only positive in Klinefelter syndrome patients and negative in other gynecomastia patients [6].

Thus, the rationale intended for this case series study was to explore the relationship between gynecomastia and both estrogen hormone blood level and estrogen tissue receptors.

PATIENTS AND METHODS

The study was conducted in the Plastic Surgery Department, Cairo University Hospital, during the period from January 2015 to February 2016. This study followed the Declaration of Helsinki. It followed the Medical Research Involving Human Subjects Act (WMO) and was approved by the Medical Ethical Review Committee of Cairo University. The specimen obtained were sent to the Pathology Department, Cairo University for histological study and to the Immunohistochemical Unit for staining and study of the receptors.

We recruited males between 18 to 60 years presenting with gynecomastia and duration more than one year. Exclusion criteria included: American Society of Anesthesia score 3 or 4 (high risk for anesthesia), patients with cancer breast and patients with previous chest surgery.

Pre-operative patient assessment and gynecomastia evaluation.

All patients were evaluated by detailed history, careful physical examination and photographed pre and post-operative.

History included: Age at onset, laterality, presence or absence of masses, presence or absence of nipple discharge or axillary lymphadenopathy, weight gain or loss and the presence of testicular masses. Besides, history of thyroid problems, liver disease, and renal disease, testicular neoplasm, hypothalamic or pituitary disorders, recent drug intake, malnutrition, chromosomal abnormality or family history of breast cancer; has been taken.

Adequate physical examination with stress on the following points was done: Testicular examination, secondary sexual characters as voice, body contour, facial and body hair, signs of hyperthyroidism, renal failure or liver disease. Also, the local examination was done to exclude any sign of breast cancer as a solid breast mass, nipple discharge or suspicious axillary lymphadenopathy.

Gynecomastia of glandular and fatty natures was differentiated by searching for a rubbery or firm, mobile, disc-like breast tissue beneath the

Nipple-Areola-Complex (NAC). Grading was done using the Cordova & Moschella (2008) classification [11].

Laboratory investigations:

Blood samples were taken from patients as routine preoperative preparation for complete blood picture, coagulation profile and liver and kidney functions.

Estradiol (E2) level was investigated in all patients. The blood samples were collected by venipuncture into plain tubes. The serum was separated from the cells in tubes labeled by the name of the patient. The hormonal assessment was performed at Cairo University Hospital, the main chemistry laboratory by immunoassays with electro-chemi-luminescent detection method using the e601 module of Cobas 6000 (Cobas 6000 analyzer series|Roche Diagnostics USA). The normal estradiol range of the laboratory was ND-56pg/ml for males.

Other hormonal studies were done for patients with suspected hormonal disturbance. The laboratory evaluation usually consists of thyroid function tests, testosterone, hCG, and LH, Dehydroepiandrosterone Sulfate (DHEAS) and prolactin. Karyotyping was done in patients with suspected chromosomal abnormality. Mammography and breast ultrasound were not done routinely unless suspicious lesion, mass or asymmetrical breast enlargement was detected upon physical examination.

Photos were taken pre-operative and post-operative in three views: Anteroposterior, dead lateral and oblique. Informed consent was taken from all patients.

Surgical procedures:

The main surgical procedures used were liposuction, excision and biopsy, reduction and biopsy.

Liposuction was done under general anesthesia, in addition to tumescence infiltrative anesthesia. Drains were not used. Compressive elastic garments were worn for 4-6 weeks. Routine post-operative follow-up was done after 1, 2, and four weeks and after three months. Excision was done via the periareolar incision. The suction drain was inserted in the subcutaneous plane with dermal closure by interrupted inverted Vicryl 3-0 sutures and skin closure by subcuticular Monocryl 3-0 sutures. Compression garments were worn for 4-6 weeks. Skin reduction was made by Benelli approach (the concentric circumareolar approach) or by the modified wise pattern "inverted T" approach.

Histopathological examination and immunohistochemical detection of estrogen receptors:

All gynecomastia specimens were fixed in Formalin 10% solution and sent to the pathology lab for histopathological examination. Routinely, they were processed and embedded in paraffin wax blocks, and then four μ thick sections were prepared. One section was stained with the standard Haematoxylin and Eosin (H & E) stain as a routine to be examined by the pathologist to establish the histopathological diagnosis and another section was prepared for immunohistochemical analysis on positively charged slides.

Immunohistochemical staining was carried out by using prediluted Rabbit Monoclonal anti-ER, Clone EP1 "LAB Genemed Biotechnologies, Inc, South San Francisco, CA 94080, U.S.A" which particularly detects the ER- α protein located in the cell nuclei of ER-expressing cells. Rabbit Monoclonal Antibody recognizes a protein of 67kDa, which is identified as ER- α .

The measurement of the ER- α immunostained nuclei and their percent to the total nuclei in the slides were done. The presence of ER- α in gynecomastia tissue biopsies was correlated to the patient's age, nature of gynecomastia and whether gynecomastia is unilateral or bilateral. Furthermore, the percentage of ER- α immunostained nuclei was correlated to the grade of gynecomastia according to Cordova & Moschella (2008) classification [11].

Outcome measures:

The primary outcome measure was the prevalence of estrogen receptors alpha (ER- α) in the breast tissue. The secondary outcome measure was the estrogen hormone (E2) blood level.

Statistical analysis:

All statistical tests were done using a significance level of 95%. A value of $p < 0.05$ was considered statistically significant. SPSS software (Statistical Package for the Social Sciences, Version 20.0, SSPS Inc., Chicago, IL, USA) was used for the statistical analyses. Data were presented as (mean \pm SD) or median (range) for continuous variables and as a frequency for categorical variables. Comparisons between groups were made using Chi-square test and Phi-Cramer test for categorical variable and the t -test for continuous variables.

RESULTS

All subjects with gynecomastia for more than one year and aged from 18 to 60 who came to the

center and were eligible for surgical intervention were asked to participate in the study. Some subjects refused to participate, and others were excluded before surgery because they were at high risk for anesthesia (ASA 3 and 4), leaving only 22 participants for surgical intervention and postoperative follow-up. No subject was excluded after surgery during the follow-up period.

Baseline characteristics and operative procedures:

Twenty-two subjects were included in the analysis of this study. Seventeen patients (77%) had bilateral gynecomastia and five patients (23%) unilateral. The mean age of presentation was 28.3 years with a range from 18 to 59 years old, and 75% of them are teenagers/young adults. The main presenting symptoms were the psychological embarrassment, lack of self-confidence and withdrawal from physical and social activities.

No apparent cause of gynecomastia was detected in 17 cases by history, examination, and investigations. While 4 cases were secondary to another disease; Klinefelter syndrome, renal failure on dialysis, post massive weight loss and ambiguous genitalia transgender.

According to Cordova and Moschella (2008) classification, fifteen patients presented with grade II, five patients with grade III and two patients with grade IV.

Thyroid hormone was high in two case and low in other two cases. Estrogen hormone was normal in the majority of subjects (20 cases) while it was elevated only in two subjects.

Periareolar excision was done in 11 subjects, liposuction in 7 and reduction surgery in 4 subjects. Biopsies were obtained from patient's breast tissue post-operatively and were sent for pathology assessment. Details of patients' demographics and clinicopathological data are shown in (Table 1).

Histopathological examination:

Histopathological examination of the biopsies revealed that 14 subjects (63.6%) were glandular in nature and only eight subjects (36.4%) were fatty in nature.

Twelve cases were found to be ER- α positive, while 8 cases were found to be ER- α negative. In two cases pathological examination revealed absent ducts in the examined tissues, and they were considered as negative for ER- α (total negative 10 cases), as shown in (Table 2).

The relationship between the nature of gynecomastia and other clinicopathological factors:

There was no significant ($p>0.05$) association between the nature of gynecomastia; either glandular or fatty and the side, the grade, the blood level of thyroid hormone and the blood level of estrogen hormone. However, the age of presentation was significantly ($p=0.03$) lower in cases with fatty gynecomastia (22.38 ± 4.17 years) than in cases with glandular gynecomastia (31.64 ± 13.51 years). Moreover, positive ER- α significantly ($p=0.005$) higher in cases with glandular gynecomastia (11 cases positive) than in cases with fatty gynecomastia (1 case, only), as shown in (Table 3).

The relationship between ER- α and other clinicopathological factors:

Statistically, there was no significant ($p>0.05$) association between ER- α and both the grade of gynecomastia and the blood level of thyroid hormone. However, the age of presentation was significantly ($p=0.04$) lower in cases with negative ER- α (22.90 ± 3.84 years) than in cases with positive ER- α (32.75 ± 14.37 years). Moreover, all cases with negative ER- α were significantly ($p=0.030$) bilateral (10 cases) more than in cases with positive ER- α (7 cases out of 12), as shown in (Table 3).

Table (1): Patients' demographics and clinicopathological data by nature of gynecomastia.

	Glandular	Fatty	p-value
Number of cases	14	8	
<i>Age:</i>			
Mean (SD)	31.64 (13.51)	22.38 (4.17)	0.03
Minimum	18	18	
Maximum	59	30	
<i>Side:</i>			
Bilateral	9	8	0.076
Unilateral	5	0	
<i>Grade:</i>			
Grade 2	10	5	0.126
Grade 3	4	1	
Grade 4	0	2	
<i>Thyroid hormone:</i>			
High	1	1	0.508
Low	2	0	
Normal	11	7	
<i>Procedure:</i>			
Excision	9	2	0.118
Liposuction	4	3	
Reduction	1	3	

Table (2): Estrogen hormone and estrogen receptors- α ratio by nature of gynecomastia.

	Glandular	Fatty	p-value
Number of cases	14	8	
<i>Estrogen hormone:</i>			
Normal	12	8	0.394
Elevated	2	0	
<i>Estrogen receptors-α:</i>			
Normal	3	7	0.005
High	11	1	

Table (3): Patients' demographics and clinicopathological data by Estrogen Receptors- α positivity or negativity.

	ER- α positive	ER- α negative	p-value
Number of cases	12	10	
<i>Age:</i>			
Mean (SD)	32.75 (14.37)	22.90 (3.84)	0.04
Minimum	18	18	
Maximum	59	30	
<i>Side:</i>			
Bilateral	7	10	0.03
Unilateral	5	0	
<i>Grade:</i>			
Grade 2	9	6	0.267
Grade 3	3	2	
Grade 4	0	2	
<i>Thyroid hormone:</i>			
High	0	2	0.255
Low	1	1	
Normal	11	7	

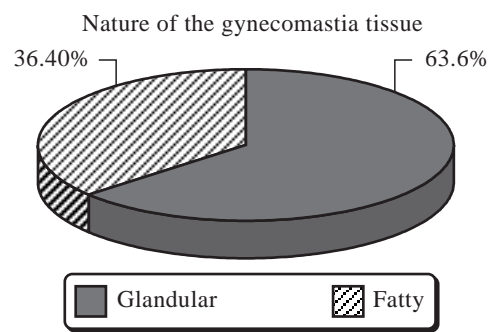


Fig. (1): Percentage of glandular versus fatty nature.

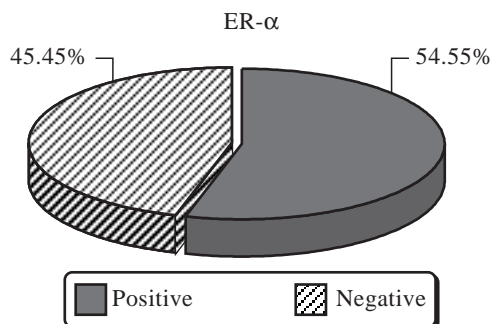


Fig. (2): Percentage of ER- α positive and negative.

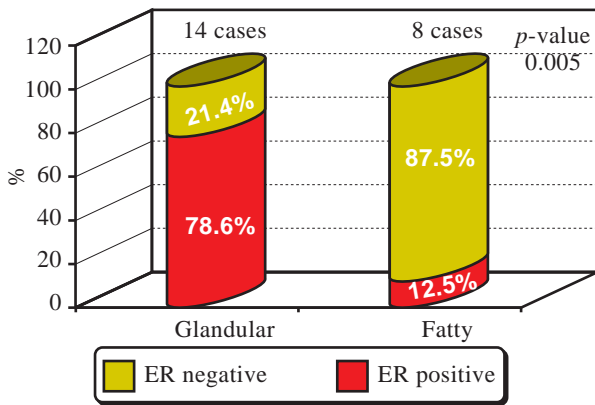


Fig. (3): Shows distribution of ER- α among different natures of gynecomastia patients.

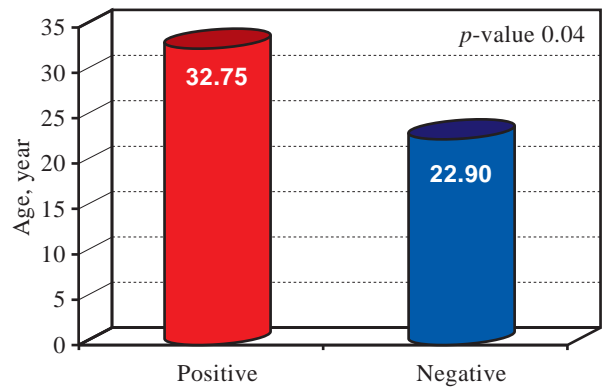


Fig. (4): The age of presentation by ER- α .

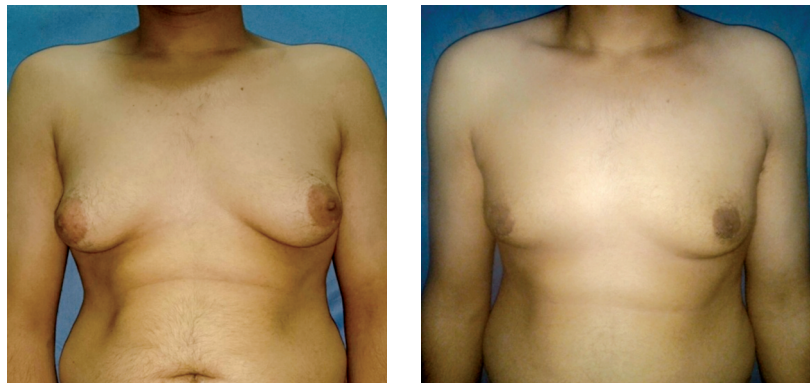

Fig. (5): Pre-operative (left) and post-operative photo (right) to the case of liposuction.

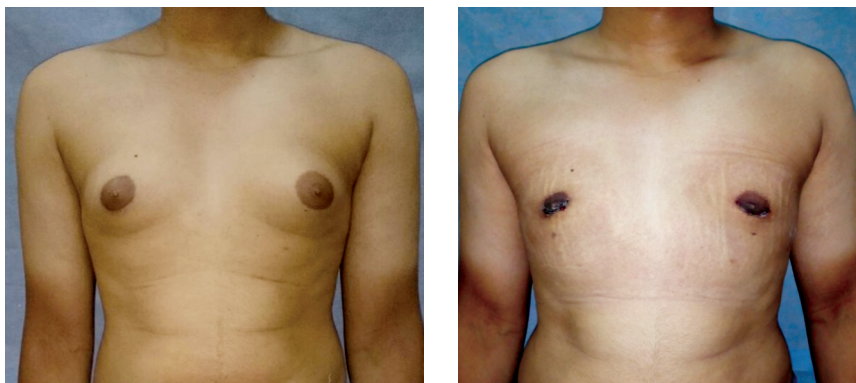


Fig. (6): Pre and post-operative photos of patient with breast tissues excision via periareolar incision.

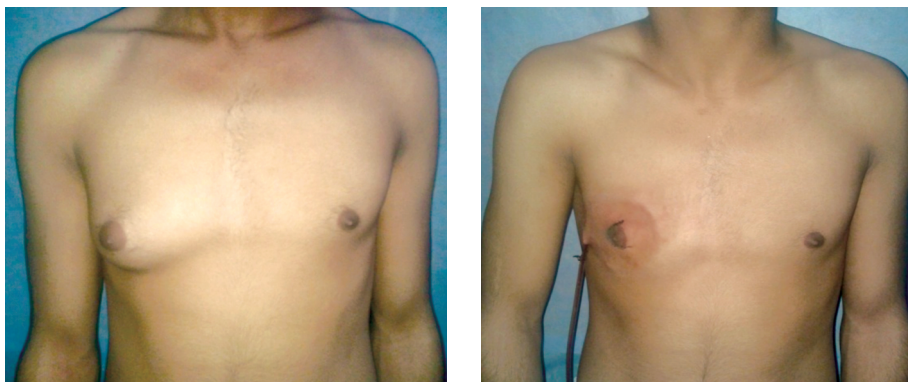


Fig. (7): Pre and post-operative (5 days) photos of patient with unilateral gynecomastia for whom excision of breast tissues via periareolar incision was done and drain inserted.

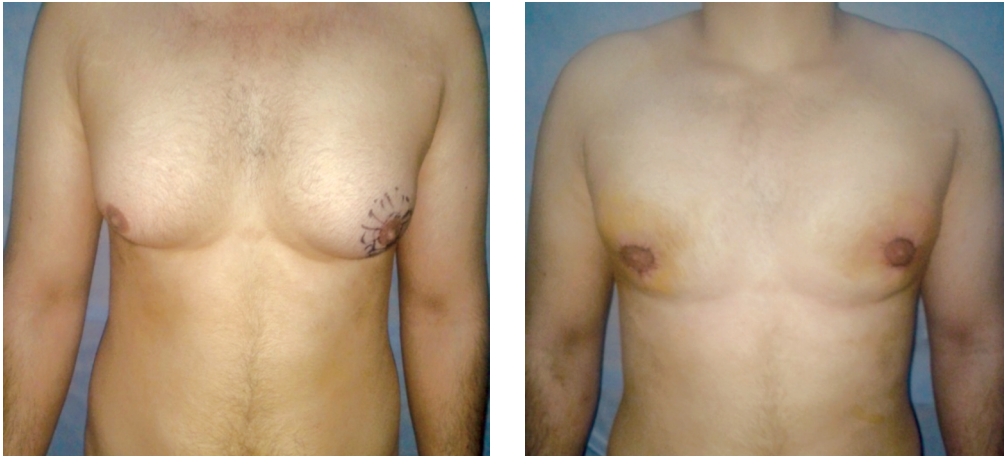

Fig. (8): Pre and post-operative photos of patient with bilateral gynecomastia for whom concentric circumareolar reduction (Benelli approach) was done.

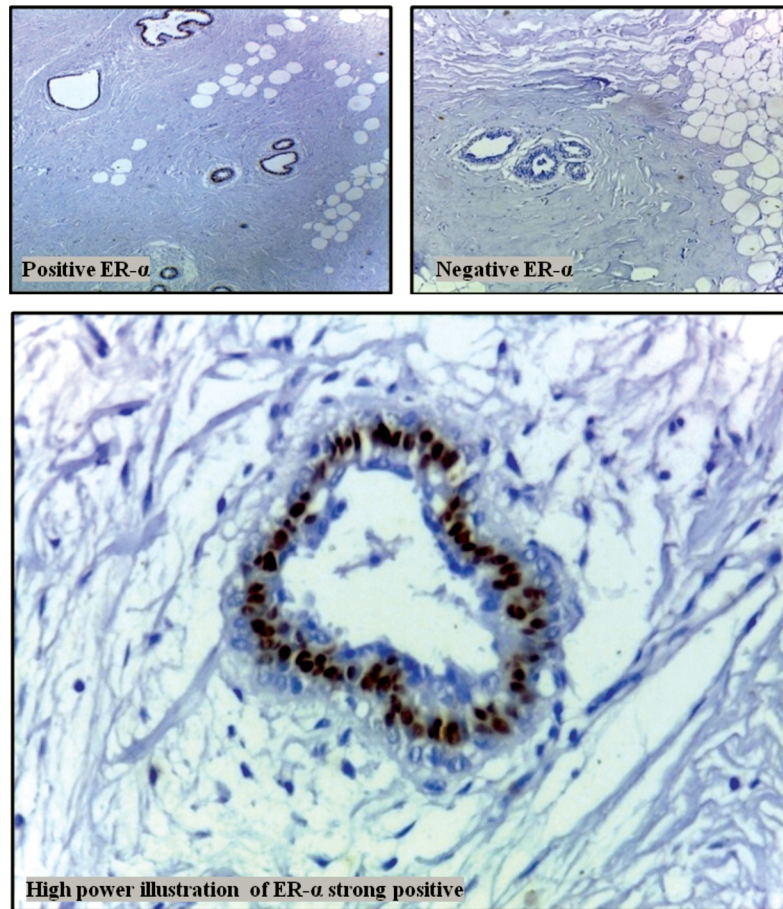


Fig. (9): Gynecomastia tissues immunohistochemically stained with ER- α .

DISCUSSION

Claudius Galenus, the famous physician in the second century A.D., was the first to introduce the term “gynecomastia” which means woman “gyne” and breasts “mastos” [12,13]. However, the first surgical attempt to treat gynecomastia was introduced in the seventh century by Byzantine physician Paulus of Aegineta [12].

Histologically, Gynecomastia is described as a benign progressive proliferation of the male breast's glandular tissue. Clinically, it is defined as the presence of a rubbery or firm mass from the nipples, and it often presents as a diffuse or a discrete retro-areola lump [14]. From the surgical point of view, Gynecomastia is designated as persistent non-malignant enlargement of the male breast that motivates patients to seek treatment [15].

The male breast is a region that symbolizes manhood and strength, and the male chest is supposed to be flat and muscular. Thus, gynecomastia is annoying for patients. The Ideal male chest is clearly seen in Leonardo Da Vinci's painting "The Vitruvian Man." [16].

Physiologically, it is well documented that estrogen has a role in the breast. Estrogen provokes ductal and periductal tissues proliferation and differentiation. It is evident that neonatal gynecomastia is associated with the exposure to maternal estrogen. Also, there is a transient rise of estrogen comparable to testosterone at puberty which corrects by time. Finally, increased activity of aromatase in the local tissues in older adults leads to higher production of estrogen explaining the senile gynecomastia [17].

Over the past two decades, many studies were conducted expanding our knowledge of the etiology of gynecomastia which resulted in the suggestion of new suggested therapies based on the pathophysiology of the disease [18,19].

Sources of estrogen in males include direct secretion from the testes and peripheral aromatization of androgens to estrogen. Other mechanisms known to contribute to the estrogen/androgen imbalance include exposure to exogenous estrogen, increased estrogen secretion, decreased secretion of testosterone by the testes [20]. There are many estrogen-like compounds, such as digoxin and phytoestrogens, were found to cause enlargement in the breast tissue [21].

The current study results showed that the majority of cases have bilateral gynecomastia. No apparent cause of gynecomastia was detected in the majority of cases. Fifteen patients presented with grade II. Estrogen hormone was elevated only in two subjects. Thyroid hormone was high in two case and low in other two cases. Surgical procedures done were periareolar excision, liposuction and reduction surgery.

More than 60% of cases have glandular gynecomastia. Twelve cases were found to be ER- α positive. Age of presentation was significantly lower in cases with fatty gynecomastia than in cases with glandular gynecomastia. In addition, the age of presentation was significantly lower in cases with negative ER- α than in cases with positive ER- α . Moreover, positive ER- α was significantly detected in cases with glandular gynecomastia. Also, all cases with negative ER- α were bilateral cases while more than half the cases with positive ER- α was bilateral.

Studies evaluating the relationship between gynecomastia and estrogen receptors have been mainly in the form of histopathological data presentations after mammoplasty.

One study by Poulsen et al., found two (10%) out of 20 gynecomastia patients were ER positive. The ratio of ER-positive cases in this study is much lower than our study. The low ratio in this study may be due to old less sensitive methods of detection of ER which didn't differentiate subtypes of estrogen receptor [3]. On the other hand, a study by Andersen et al., showed a higher percent (86%) have ER positive. In this study, immunohistochemical staining was done using monoclonal antibodies. However, it was not mentioned whether ER- α or ER- β was measured. The nonspecific measurement may attribute to the high ratio of ER-positive cases in that study [4].

Another study detected no ER in any of seven young patients (16-17 years). However, they used old methods of staining. Patient age group in this study was excluded in ours because gynecomastia at that age is usually transient and reversible [22].

Chongyu examined the relationship of the type of gynecomastia histology and estrogen receptor in 21 cases of gynecomastia. The results showed that the positive rate of estrogen receptors in florid gynecomastia was high, and an increase in the positive rate was co-occurred with a hyperplasia of mammary duct epithelium [23].

In a study by Sasano et al., in which estrogen, androgen, and aromatase expression were investigated in 30 gynecomastia cases, ER expression and androgen expression were detected in 100% of ductal cells and epithelium cells and aromatase expression was detected in 37% of cases. Authors in this study specified neither the type of ER nor the nature of gynecomastia whether glandular or fatty [24].

In another study, Pensler et al., reported that there was no ER increase in 34 gynecomastia patients. Only three patients with Klinefelter syndrome exhibited high amounts of estrogen and progesterone receptors. However, the charcoal method in duplicate-used for the detection of ER-can detect cytosolic receptors only. All patients in that study were adolescents. Period of symptoms was not mentioned. In our study, we excluded patient with symptoms less than one year because they usually need no intervention [6].

In a study by Calzada et al., (2001), staining of Androgen Receptors (AR) and (ER) in a group

of twelve body builders who administer anabolic steroids was done. There was an increase in estradiol levels in 45% of the subjects. The major concentration of ER was localized in the cytosol and nucleus, whereas, the major concentration of AR was confined in the cytosol. Authors concluded that presence of estradiol and androgen receptors in gynecomastia tissue suggests that gynecomastia is a hormone-dependent event. The number of ER-positive cases was not mentioned in the study. The population of this study is limited to secondary gynecomastia patients who administer anabolic-androgen steroids [25].

A study from 2001 to 2009 on 50 cases of pubertal gynecomastia was done by Nicoletti et al., ER- α and ER- α RNA expression in tissue samples of pubertal gynecomastia cases were evaluated. ER- α was expressed at high rates in all stromal cells, whereas ER- α and ER- α were hardly detected in epithelial cells. The researchers suggested that stromal cells and ER- α might have a role in the development of pubertal gynecomastia. Tissue sample here was limited to the pubertal age group (age range was 10.7-17.8 years). Nature of gynecomastia was not taken into consideration. Estrogen receptors were evaluated using RT-PCR RNA encoding [26].

In a recent study by Eren et al., Genetic analysis of blood samples from 107 male adolescents with gynecomastia and 97 controls was done. The correlations between gynecomastia and ER- α gene and ER- α gene polymorphisms were investigated. Increased E2 levels and ER- α gene polymorphism may explain why some adolescents have gynecomastia. Leptin receptor polymorphism may increase susceptibility to gynecomastia. All patients in this study were adolescents [18].

Tamoxifen, a selective estrogen receptor modulator, has been used as a first line medication in gynecomastia. It has been effective in men with prostate cancer and boys with persistent pubertal gynecomastia. It has shown the efficacy of up to 90% for the resolution of gynecomastia. The success of Tamoxifen is added to the evidence for the role of estrogen receptors in gynecomastia. However, it is only useful in early cases, and sometimes recurrence or incomplete resolution occurs [7].

The association between ER and gynecomastia is evident. However, further research is required to investigate the role of selective antiestrogen receptor drugs in the management of glandular gynecomastia.

Conclusion:

Finally, we conclude that there is an association between ER- α and glandular gynecomastia. Thus, it may play a role in its development. A further large-sample study is recommended to allow a real evidence and quantification of this relationship. Moreover, the investigations of the role of anti-estrogen drugs in downgrading gynecomastia and preventing its recurrence after surgery in adults with glandular gynecomastia are recommended.

Declaration of interest:

All authors declare that no conflict of interest could be perceived as prejudicing the impartiality of the research reported.

Funding:

This research did not receive any specific grant from any funding agency in the public, commercial or not-for-profit sector.

REFERENCES

- 1- Kumanov P., Deepinder F., Robeva R., Tomova A., Li J. and Agarwal A.: Relationship of adolescent gynecomastia with varicocele and somatometric parameters: A cross-sectional study in 6200 healthy boys. *J. Adolesc. Health*, 41: 126-31. [PubMed], 2007.
- 2- Karp N.S.: Gynecomastia. In: Thorne C.H., Beasley R.W., Aston S.J., Bartlett S.P., Gurtner G.C. and Spear S.L., editors. *Grabb and Smith's Plastic Surgery*. 6th ed. Philadelphia: Wolters Kluwer Lippincott Williams & Wilkins; pp. 616-20, 2006.
- 3- Poulsen H.S., Hermansen C., Andersen, J.A., Anderson, H.U. and Jensen J.: Gynecomastia: Estrogen and androgen receptors: A clinical-pathological investigation. *Acta Pathol. Microbiol. Immunol. Scand. A*, 93: 229-33, 1985.
- 4- Andersen J., Orntoft T.F., Andersen J.A. and Poulsen H.S.: Gynecomastia: Immunohistochemical demonstration of estrogen receptors. *Acta Pathol. Microbiol. Immunol. Scand. A*, 95: 263-7, 1987.
- 5- Izabella Czajka-Oraniec, Wojciech Zgliczynski, Alina Kurylowicz, Michal Mikula and Jerzy Ostrowski: Association between gynecomastia and aromatase (CYP19) polymorphisms. *European Journal of Endocrinology*, 158 (5): pp. 721-7, 2008.
- 6- Pensler J.M., Silverman B.L., Sanghavi, Goolsby C., Speck G., Brizio-Molteni L., et al.: Estrogen and progesterone receptors in gynecomastia. *Plastic and Reconstructive Surgery*, 106 (5): 1011-13, 2000.
- 7- Narula H.S. and Carlson H.E.: Gynaecomastia-pathophysiology, diagnosis and treatment. *Nat. Rev. Endocrinol.*, 2014 Nov.; 10 (11): 684-98, 2014.
- 8- John E., Hall P. and Arthur C. Guyton: *Guyton and Hall Textbook of Medical Physiology*. Available at: <http://vet.uokufa.edu.iq/staff/falah/Textbook of Medical Physiology.pdfm>, 2011.
- 9- Tarrant A.M., Atkinson S. and Atkinson M.J.: Estrone and estradiol-17 beta concentration in tissue of the scler-

- actinian coral, *Montiporaverrucosa*. *Comp Biochem. Physiol. A MolIntegr. Physiol.*, Jan., 122 (1): 85-92, 1999.
- 10- Rochira V., Granata A.R., Madeo B., Zirilli L., Rossi G. and Carani C.: Estrogens in males: What have we learned in the last 10 years? *Asian J. Androl.*, Mar., 7 (1): 3-20, 2005.
- 11- Cordova A. and Moschella F.: Algorithm for clinical evaluation and surgical treatment of gynecomastia. *J. Plast. Reconstr. Aesthet. Surg.*, 61 (1): 41-9, 2008.
- 12- Diamandopoulos A.A., Kassimatis T.I. and Goudas P.C. Paulus Aegineta: The Pioneer of Plastic Surgery Evolution and Comparisons. *Hospital Chronicles*, 2 (2): pp. 83-88, 2007.
- 13- Cederna P.S.: Correction of Gynecomastia. In J.P.R. Bahman Guyuron, Elof Eriksson, John A. Persing, Kevin C. Chung, Joseph Disa, ArunGosain, Brian M. Kinney, ed. *plastic surgery indications and practice*. Elsevier-Health Sciences Division, pp. 727-36, 2009.
- 14- Lee S.W., Kwak D.S., Jung I.S., Kwak J.H., Park J.H., Hong S.M., Lee C.B., Park Y.S., Kim D.S., Choi W.H. and Ahn Y.H.: Partial Androgen Insensitivity Syndrome Presenting with Gynecomastia. *EndocrinolMetab (Seoul)*. Jun., 30 (2): 226-30, 2015.
- 15- Hammond D.C.: Management of Gynecomastia. In D.C. Hammond, ed. *Atlas of aesthetic breast surgery*. Elsevier Saunders, pp. 195-208, 2009.
- 16- Gheita A. and Atiyeh B.S.: Gynecomastia and Male Chest Contouring. In B. S. Atiyeh & M. Costagliola, eds. *Body Contouring Following Bariatric Surgery And Massive Weight Loss-Post-Bariatric Body Contouring*. Bentham Science Publishers, pp. 112-120. Available at: <http://www.eurekaselect.com/51074/volume/1>, 2012.
- 17- Ranasinghe L.D., Subasinghe C.J., Bulugahpitiya D.U.S. and Muthukuda D.T.: A clinical approach to gynecomastia. *Sri Lanka Journal of Diabetes Endocrinology and Metabolism*. 5 (1): pp. 23-27. Doi: <http://doi.org/10.4038/sjdem.v5i1.7269>, 2015.
- 18- Erena E., Edgunlub T., Korkmaz H.A., Cakird E.D.P., Demire K., Cetinf E.S. and Celikg S.K.: Genetic variants of estrogen beta and leptin receptors may cause gynecomastia in adolescent. *Gene.*, 541 (2): pp. 101-6. Available at: <http://dx.doi.org/10.1016/j.gene.2014.03.013>, 2014.
- 19- Bedognetti D., Rubagotti A., Conti G., Francesca F., De Cobelli O., Canclini L., Gallucci M., Aragona F., Di Tonno P., Cortellini P., Martorana G., Lapini A. and Boccardo F.: An Open, Randomised, Multicentre, Phase 3 Trial Comparing the Efficacy of Two Tamoxifen Schedules in Preventing Gynaecomastia Induced by Bicalutamide Monotherapy in Prostate Cancer Patients. *Eur. Urol.*, Feb., 57 (2): 238-45. Doi: 10.1016/j.eururo.2009.05.019, 2010.
- 20- Karnath B.M.: Gynecomastia. *Rev. Clin. Signs*, pp. 45-51, 2008.
- 21- Adolescent Health Care: A Practical Guide 4th Edition (March 2002): by Lawrence S. Neinstein (Editor) By Lippincott Williams & Wilkins Publishers.
- 22- Lee K.O., Chua D.Y.F. and Cheah J.S.: Oestrogen And Progesterone Receptors In Men With Bilateral Or Unilateral Pubertal Macromastia. *Clinical Endocrinology*. 32 (1): pp. 101-5. Available at: <http://doi.wiley.com/10.1111/j.1365-2265.1990.tb03755>, 1990.
- 23- Chongyu W.: The Relationship on The Type of The Histology And Estrogen Receptor in Gynecomastia. *Journal of Changzhi Medical College*, 9 (1). Available at: http://en.cnki.com.cn/Article_en/CJFDTotal-CZYX199501000.htm, 1995.
- 24- Sasano H., Kimura M., Shizawa S., Kimura N. and Nagura H.: Aromatase and steroid receptors in gynecomastia and male breast carcinoma: An immunohistochemical study. *J. Clin. Endocrinol. Metab.*, Aug., 81 (8): 3063-7. Available at: <http://press.endocrine.org/doi/abs/10.1210/jcem.81.8.8768875>, 1996.
- 25- Calzada L., Martinez J.M. and Pedrón N.: Measurement of androgen and estrogen receptors in breast tissue from subjects with anabolic steroid-dependent gynecomastia. *Life Sci.*, Aug. 17; 69 (13): 1465-9, 2001.
- 26- Nicoletti G.F., D'Andrea F., Ferraro G., Romanucci V., Renzullo A., Accardo G., Sacco V., Pannone G., Bellastella A. and Pasquali D.: Differential expression of estrogen receptor α and β transcripts in tissues and primary culture cells from pubertal gynecomastia. *J. Endocrinol. Invest.*, Feb., 35 (2): 150-3. Doi: 10.3275/7737, 2012.